

Special AT-rich sequence binding-protein 2 (SATB2)

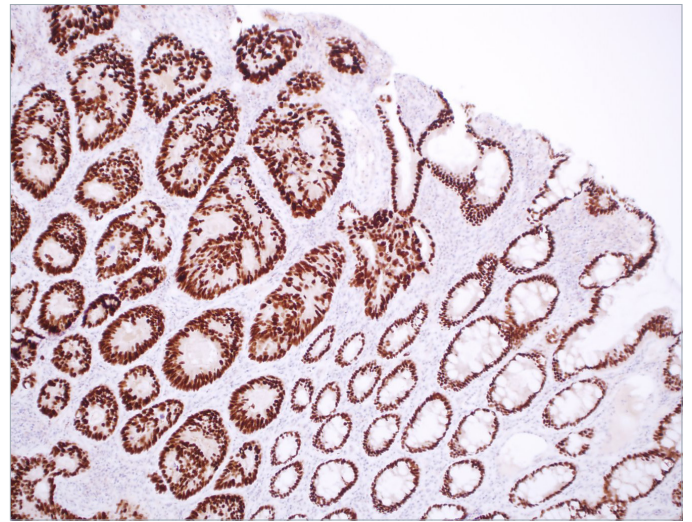
I. Introduction

It is estimated that 3% to 5% of all cancers present as a metastasis from an unknown primary site, also known as cancer of unknown primary (CUP).¹ For these CUP cases, immunohistochemistry (IHC) may be utilized to narrow the range of diagnostic alternatives and, when possible, establish a tentative diagnosis and most likely site of origin.

Approximately, 50% to 60% of these cancers are adenocarcinomas, and autopsy studies have identified the primary site to be of colonic origin in 11% of these cases. Despite an increasing use of IHC, the primary site cannot be identified in more than 80% of these cases.² Clinical management of these patients can be problematic, as the selection of appropriate systemic chemotherapy or targeted agents often depends on the specific cancer type. An increased array of cancer cell type-specific antibodies would be of substantial benefit to optimize the diagnostic procedure when resolving differential diagnostic alternatives for CUP.¹

At present there is no established specific marker for glandular cells of the lower gastrointestinal tract. Several protein expression patterns have been scrutinized and various markers have been tested in large series of different tumors. A few antibodies that provide useful information have been identified to confirm or reject a diagnosis of colorectal carcinomas (CRC). The most accepted antibody for clinical differential diagnostics is cytokeratin 20 (CK20). CK20 is an intermediate filament protein selectively expressed in glandular cells of the gastrointestinal (GI) tract, and is a highly sensitive marker. However, the specificity of CK20 alone is relatively low because this keratin is also expressed in the gastric epithelium, urothelium, and epidermal Merkel cells. In CRC, the expression of CK20 is generally preserved in metastases. Antibodies detecting caudal type homeobox 2 (CDX-2) protein and cadherin-17 (CDH-17) have also proven useful in the differential diagnosis of CRC because both of these proteins are selectively expressed at relatively high levels in cells of the whole GI tract. Unfortunately in cases of unknown primary lesions, CDX-2 has a relatively low predictive power because it is also expressed in gastric carcinomas, lung adenocarcinomas, and ovarian mucinous tumors.³ CDH-17 lacks in specificity as seen by the fact that it is also expressed in gastric, pancreatic, and biliary adenocarcinomas.⁴ In clinical practice, CK20 is often utilized in combination with other markers, such as the presence of CDX-2 or the absence of cytokeratin 7 (CK7), to increase the accuracy for determining a diagnosis of CRC.

The special AT-rich sequence binding-protein (SATB2) is a DNA-binding protein, which specifically binds to nuclear matrix attachment regions of DNA. SATB2 is involved in regulation of transcription and chromatin remodeling, and shows a remarkable degree of evolutionary conservation, with a difference of only three amino acids between mouse and human. Recently, several antibodies against SATB2, mouse monoclonal, rabbit polyclonal, and rabbit monoclonal, have been used for clinical diagnosis of GI tract carcinomas.^{1-2,4-5}



Above: The colorectal adenocarcinoma on the left side of the panel shows strong, diffuse nuclear staining by rabbit monoclonal anti-SATB2. Notice on the right side of the panel adjacent to the carcinoma is normal-appearing colonic mucosa that also displays positive staining by the antibody.

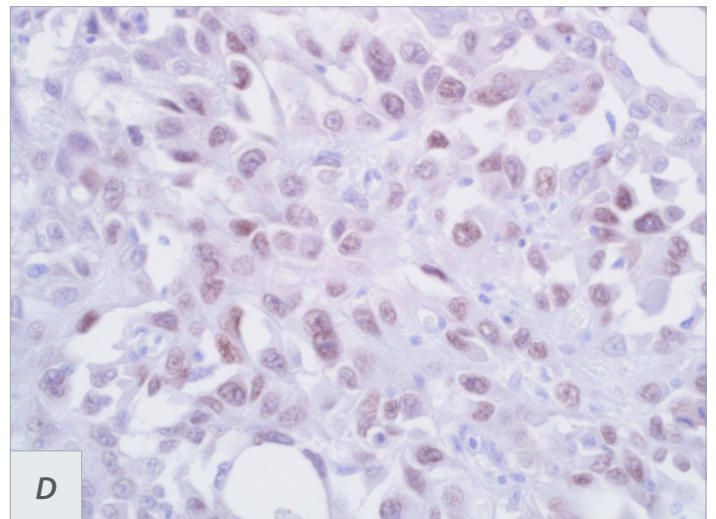
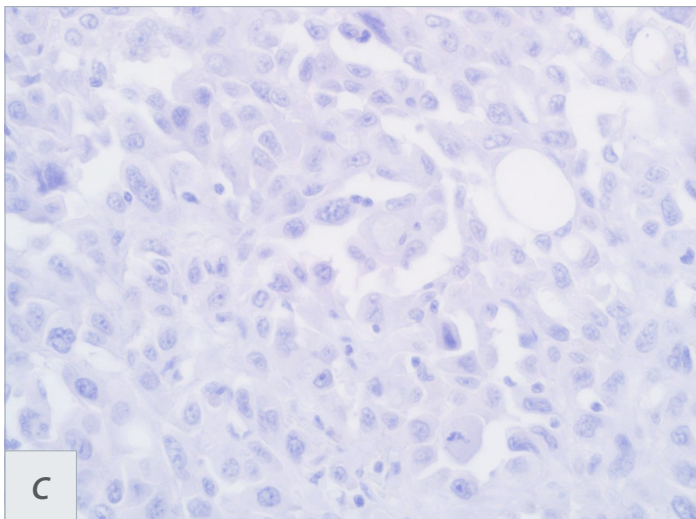
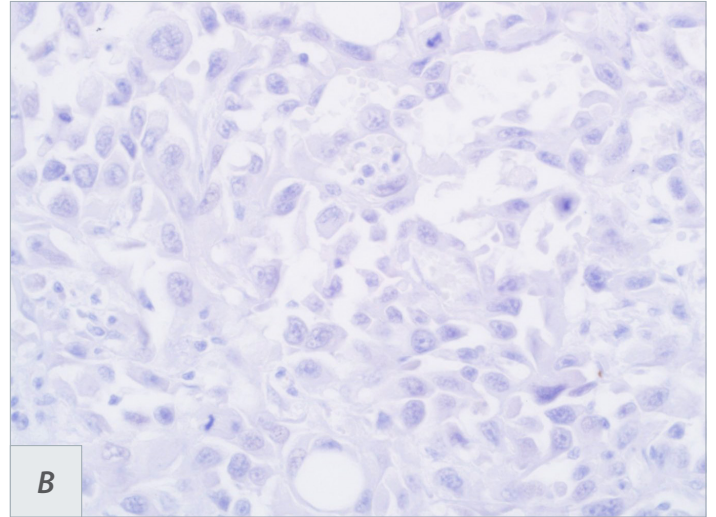
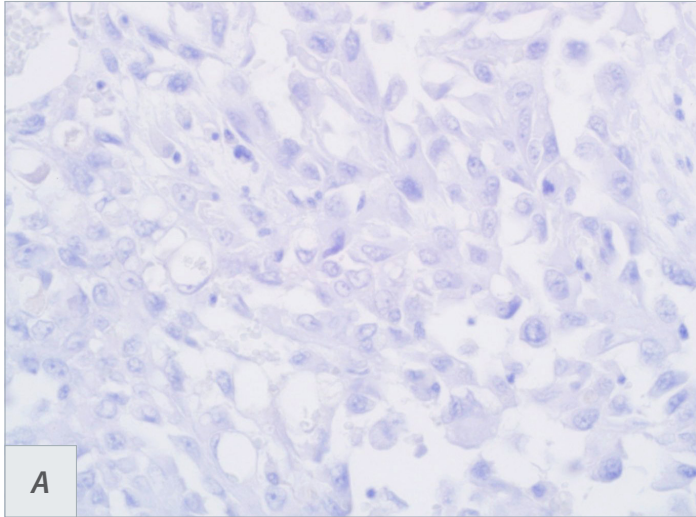
II. Normal tissue distribution of the SATB2

Rabbit polyclonal anti-SATB2 screening of SATB2 expression in normal tissues has found strong nuclear expression in almost all glandular cells lining the lower GI tract, including the appendix, colon, and rectum. Strong nuclear expression was also detected in a subset of neuronal cells from the cerebral cortex and hippocampus. A subset of lymphoid cells, cells in the seminiferous ducts of the testis, and cells lining the epididymis has shown weak-to-moderate positivity. Rabbit monoclonal anti-SATB2 showed very similar results to the findings of polyclonal anti-SATB2 without the unwanted nuclear staining in lymphoid cells. The other normal cell types demonstrated no SATB2 expression.^{2,6}

III. Clinical applications of SATB2

An IHC analysis using rabbit polyclonal anti-SATB2 has shown a distinct nuclear expression with both a strong intensity and a high fraction of positive tumor cells in the majority of analyzed CRC. A total of 1336 of 1558 (85.8%) primary CRC and 205 of 252 (81.3%) metastases showed positive SATB2 immunoreactivity in one study.² SATB2 was positive in 189 of 194 (97.4%) samples of normal colonic mucosa.²

We tested our rabbit monoclonal anti-SATB2 in both well-differentiated and poorly differentiated CRC. SATB2 expression has been seen in almost all cases of CRC, with a noted lower SATB2 expression in the poorly differentiated CRC,



Above: Immunohistochemical analysis of a poorly differentiated medullary carcinoma of the colon is seen as **A)** Cytokeratin 20 staining is absent. **B)** CDX-2 staining is also completely absent. **C)** Cadherin-17 is also notably negative in this MC. **D)** Rabbit monoclonal anti-SATB2 shows most of the tumor cells expressing SATB2 protein, at low level.

not only in the staining intensity but also staining extent.⁶ Also a lower fraction of SATB2-expressing CRC cells was found in CRC metastases, but a majority of cases showed a low-to-moderate level of expression in both metastases from regional lymph nodes and at distant sites. In a study using rabbit monoclonal anti-SATB2, we recruited 67 CRC cases, 40 gastric carcinomas (GC), 21 hepatocellular carcinomas (HCC), 8 intrahepatic cholangiocarcinomas (ICC), 13 pancreatic ductal carcinomas (PDC), 10 GI stromal tumors (GIST), 22 breast invasive ductal carcinomas (IDC), and 27 lung carcinomas (LCA). One full section from each case was stained with rabbit monoclonal anti-SATB2. Of 67 CRC, 3 cases were negative for SATB2 expression (sensitivity 95.5%). All three SATB2-negative cases were poorly differentiated (2 mucinous and 1 signet ring cell). SATB2 was expressed in 11 of 40 cases of GC (27.5%). 2/21 (10%) HCCs demonstrated weak expression of SATB2, as did 2/8 ICC (25%)

and 3/13 cases (23%) of PDC. All 10 GISTs and 22 breast IDCs were negative for SATB2 (0%), while only 3/27 (11%) lung carcinomas showed weak and focal SATB2 staining. The data generated indicate that the rabbit monoclonal anti-SATB2 has a sensitivity of 95.5% and a specificity of 85%.⁶

Medullary carcinoma (MC) of the colon and rectum is a rare, distinct variant of colorectal carcinoma, first described nearly 2 decades ago. The World Health Organization (WHO) recognized MC as a separate entity of CRC in the 2010 edition of WHO Classification of Tumours of the Digestive System. MC typically presents as a large-sized tumor of the right side of the colon, especially in the cecum, in elderly patients.

Histologically, MC presents with solid sheets, nests, or trabeculae of intermediate to large polygonal tumor cells with high nuclear/cytoplasmic

ratio; vesicular nuclear chromatin and conspicuous to prominent nucleoli; amphophilic cytoplasm; pushing tumor border; peritumoral and intratumoral lymphocytic infiltration; and minimal or no glandular formation. Medullary carcinoma tends to present with a high tumor stage (T3 or T4) but has a favorable prognosis (less lymph node and distant metastasis) compared with poorly differentiated adenocarcinoma or neuroendocrine carcinoma of the large intestine.³

Given the undifferentiated morphology and reduced or absent expression of both CK20 and CDX-2 in these tumors, a diagnostic challenge can be encountered, especially when working on a carcinoma of unknown primary (CUP). To complicate this matter further, some MC cases can be positive for CK7 and negative for both CK20 and CDX-2. Therefore, more sensitive and specific markers are needed and CDH17 and SATB2 may potentially serve this purpose. In one study,⁵ 89% of MC cases were positive for CDH-17 and SATB2, respectively. Importantly, 2 CDH-17-negative cases were both positive for SATB2, and 2 SATB2-negative cases were positive for CDH-17. Therefore, CDH-17 and SATB2 are complementary and, when used together, could identify all MC.⁵

IV. Other markers available for detection of metastatic CRC

Dragomir, et al reports that SATB2 marker alone had 93% sensitivity and 77% specificity in determining CRC. The CK20 marker alone showed 93% sensitivity and 88% specificity. Similar results were observed when only metastases were analyzed.¹ When a triple combination of markers was analyzed, the phenotype CK7-/CK20+/SATB2+ had a sensitivity of 83% and a specificity of 100% in determining CRC. A similar trend was observed when metastases were analyzed.¹

The most common markers for tumors of colorectal origin include the expression of CK20, often in combination with lack of CK7, that is, the CK20+/CK7- phenotype. However, using this phenotype alone would misdiagnose a proportion of cases, because CK7 is expressed in 10% to 27% of CRCs, and focally in up to 22% of normal colonic mucosa, making it difficult to interpret results in a subset of cases.¹

In the CUP category, 33% of the tumors were CK20 positive.¹ SATB2 was detected in 93% of CRC cases, 23% in other carcinoma cases, and 41% in CUP cases. CRC cases showed a substantially larger fraction of cases with widespread SATB2 staining compared with other carcinoma cases (69% vs 3.5%). Altogether, among the 105 CRC cases, 93 were positive for SATB2, 93 were positive for CK20, and 103 were positive for either marker. A significant correlation was noted between CK20 and SATB2 staining both when all tumors in the study were considered.¹

V. Conclusion

IHC remains advantageous and the preferred method to complement diagnostics based on microscopic evaluation of hematoxylin and eosin-stained slides, despite the expanding field of new molecular markers and methods that are based on the detection of specific mutations, gene amplifications, or transcriptional profiles. IHC is imperative for differential diagnostics of metastatic carcinoma without any known primary at diagnosis, and guides further clinical investigations. It may also help in the decision of treatment in patients with metastatic CUP origin. Furthermore, IHC is important for tumor stratification, malignancy grading, and analysis of expressed proteins that yield treatment predictive information.

The detection of SATB2 protein using IHC provides a clinically relevant diagnostic tool with high specificity and sensitivity for establishing a diagnosis of CRC. Furthermore, results strongly suggest that the combination of SATB2, CDH-17 and CK20 IHC in routine practice is advantageous for differential diagnostics, as this combination has the power to identify more than 97% of all CRCs.²

References

1. Dragomir A, et al. The role of SATB2 as a diagnostic marker for tumors of colorectal origin. *Am J Clin Pathol.* 2014; 141:630.
2. Magnusson K, et al. SATB2 in combination with cytokeratin 20 identifies over 95% of all colorectal carcinomas. *Am J Surg Pathol.* 2011; 35:937-948.
3. Dennis JL, et al. Markers of adenocarcinoma characteristic of the site of origin: development of a diagnostic algorithm. *Clin Cancer Res* 2005;11:3772.
4. Su MC, et al. Cadherin 17 is a useful diagnostic marker for adenocarcinoma of the digestive system. *Mod Pathol* 2008;21:1379.
5. Lin F, et al. Cadherin-17 and SATB2 Are sensitive and specific Immunomarkers for medullary carcinoma of the large intestine. *Arch Pathol Lab Med.* 2014; 138:1015.
6. Yang G, et al. Rabbit monoclonal anti-SATB2 is a useful immunohistochemical marker for identification of malignancies of lower gastrointestinal tract. In preparation for publication.

Ordering information for SATB2 (EP281)

Volume	Part No.	Volume	Part No.
0.1 ml, concentrate384R-14	1 ml, prediluted384R-17
0.5 ml, concentrate384R-15	7 ml, prediluted384R-18
1 ml, concentrate384R-16	Positive control slides384S